Top Ten Tips for Imaging the Triangular Fibrocartilage Complex

Julianna YS Chan, Alex WH Ng, Cina SL Tong, Esther HY Hung, James F Griffith, WL Tse, WY Wong, Michael Mak, PC Ho
Department of Imaging and Interventional Radiology, Prince of Wales Hospital, The Chinese University of Hong Kong
Department of Orthopedics and Traumatology, Prince of Wales Hospital, The Chinese University of Hong Kong

1: Be familiar with the anatomy of the TFCC & 2: Be familiar with the MR features of the normal TFCC

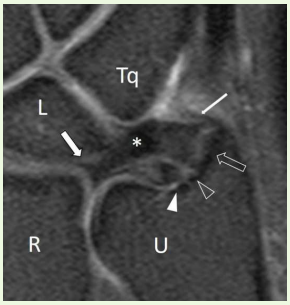

Normal attachments at the distal radius (R) and ulna (U) in coronal view.
Ulnar attachment of the articular disc (*) of TFCC onto the ulnar styloid process (block arrow) through the distal lamina, and onto the fovea of distal ulna (arrowhead) through the proximal lamina; separated by the ligamentum subcruentum (block arrowhead). **On the radial side**, TFCC is attached onto the articular cartilage over the ulnar side of the distal radius (arrow). TFCC is also reinforced by the ulnomeniscal homologue (thin long arrow).
L=lunate. Tq=triquetrum.

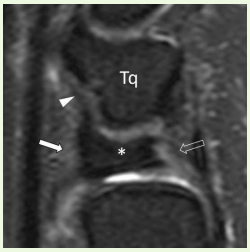

Normal attachments of the articular disc (*) in sagittal view.
Volar attachment at the volar radioulnar ligament (solid arrow) and **dorsal attachment** at the dorsal radioulnar ligament (block arrow). **Distal attachment** at the volar side of the triquetrum through the ulnotriquetral ligament (arrowhead) and ulnolunate ligament (not shown).
Normal TFCC appearance is bowtie shaped on sagittal view because it is thicker at the volar and dorsal sides. **TFCC thickness** depends on the degree of ulnar variance and is thicker in subjects with ulnar negative

3: Be familiar with Palmer's classification

I: Traumatic tear
- A: Central perforation
- B: Ulnar avulsion tear (foveal & styloid fibres) +/- Distal ulnar fracture
- C: Distal tear (ulnotriquetral & ulnolunate ligaments) +/- Attachment fracture
- D: Radial sided tear +/- Sigmoid notch fracture

II: Degenerative tear
- A: TFC wearing
- B: + Chondromalacia
- C: + TFC perforation
- D: + Lunotriquetral ligament tear
- E: + Ulnocarpal or DRUJ arthritis

4: Distinguishing traumatic vs. degenerative tears (i.e. Type 1 vs. Type 2)

Degenerative tear
- More central in location
- Less well-defined margin
- Oval in shape
- Diffusely thinned TFCC
- Asymptomatic
- Older patients
- Associated with ulnar positive variance

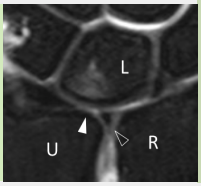

Traumatic tear
- Less central in location
- Closer to radial side within 2 to 3mm from the radial insertion
- Sharp and well-defined margin
- Slit-like appearance
- Symptomatic
- Younger patients

^A degenerative tear evidenced by diffuse thinning of the articular disc (solid arrowhead). This is a paracentral tear with residual remnant (block arrowhead) of the disc attaching on the ulnar side of the distal radius (R).

5: Distinguishing radial avulsion injury vs. paracentral tear (i.e. Type 1D vs. Type 1A)

Look for residual torn fragment!
Type A shows residual torn fragment at the radial side attachment. In type D, no residual fragment can be seen.

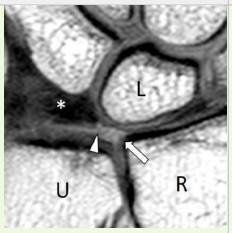

^An avulsive/ type 1D tear (arrowhead) from the radial (R) attachment (arrow). No articular disc remnant is present at the radial attachment. The articular disc (*) is retracted medially and appears lax and bunched up. L, lunate; U, ulna.

6: Assessment of foveal attachment tears (i.e. Type 1B)

Look for
- Discontinuity of the fibres
- Bare surface exposure of ulnar fovea
- Secondary signs
  - Altered morphology
  - Focal synovitis

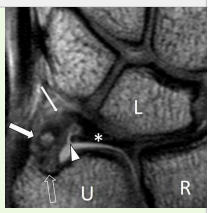

^ Nonunited fracture of tip of ulnar styloid (arrow) with residual fibres from the distal lamina of the TFCC attaching onto the fracture fragment (thin long arrow) and the native distal ulna (block arrow). Abnormal signal of TFCC is suggestive of previous sprain. There is discontinuity of the fibres from the proximal lamina of TFCC (arrowhead) on the fovea, which largely contributes to distal radioulnar joint instability.

7: Assessment of distal attachment tears (i.e. Type 1C)

Look at all three planes (especially sagittal and coronal planes). Look at the signal intensity and thickness of the ligaments, as injuries to these ligaments are usually intrasubstance partial tears or sprain rather than fibre discontinuity.

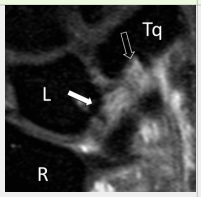

^ Abnormal high signal intensity and thickening of the ulnocarpal ligaments including the ulnotriquetral ligament (block arrow) and ulnolunate ligament (arrow) attaching onto the triquetrum (Tq) and lunate (L), suggestive of high grade sprain (partial tear).

8: Assessment of atypical tears: Dorsal-sided and volar-sided tears

Look at the sagittal and axial views for fluid or fibre discontinuity on the dorsal and volar sides of the disc.

^ There is a gap in the dorsal attachment of the articular disc of TFCC (*) filled up with fluid, suggestive of tear of the fibres of TFCC on the dorsal radioulnar ligament (arrowhead). The volar radioulnar ligament is intact and there is no fluid present (arrow).

9: Use of MR Arthrogram

Arthrogram is the gold standard of diagnosis of TFCC tears and may aid the diagnosis of the usually difficult-to-detect minor perforations and small tears especially in the periphery of the TFCC. Direct or indirect arthrograms are possible. We prefer direct arthrogram for better distension of the joint. The contrast can be injected into the radiocarpal joint under fluoroscopic or ultrasound guidance. Fluoroscopic guidance has the added benefit of detecting real time contrast leakage of the contrast into the DRUJ. If no contrast leakage into the DRUJ is observed, we can further inject contrast into the DRUJ and have a better delineation of the proximal surface of the TFCC and exclude a partial tear of the TFCC at proximal surface.

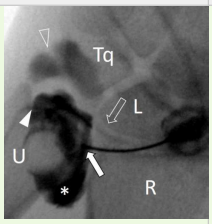

Frontal view during fluoroscopic guided injection of contrast (*) into the DRUJ. Tip of 22G spinal needle at the ulnar side of the DRUJ (arrow). Contrast material extends to the ulnar fovea (arrowhead), suggesting a tear of the proximal lamina. Diluted iodinated contrast is present in the ulnocarpal joint (block arrow) and prestyloid recess (block arrowhead) due to prior contrast injection into the radiocarpal joint before distal radioulnar joint injection. L, lunate; R, radius; Tq, triquetrum; U, ulna.

10: Application of Traction MRI

Traction can help in the diagnosis of wrist pathology and TFCC tears. We use finger traps to hold the fingers and the traction weight is suspended from the edge of the MRI gantry. The set up requires less than 5 minutes. A 7kg force for men and a 5kg force for women are applied, which are generally well tolerated.
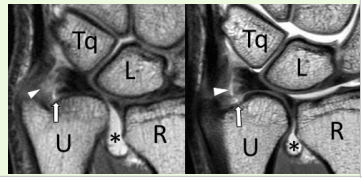
Before traction (left) and after traction (right) images showing partial tear at the proximal lamina attaching to the fovea (arrow) of the distal ulna (U). The distal lamina (arrowhead) is moderately edematous, but no gap is present to indicate torn fibers. A small effusion of the distal radioulnar joint is present. The articular surfaces of the triquetrum(Tq) and lunate (L) are better delineated on post-traction image because the joint spaces are widened and filled with fluid. R, radius.